

Final Draft
of the original manuscript:

Jung, F.; Franke, R.-P.:

**Extreme reduction of the capillary lumen in segments of the
venular legs of human cutaneous capillaries**

In: Microvascular Research (2009) Elsevier

DOI: 10.1016/j.mvr.2009.02.010

Extreme reduction of the capillary lumen in segments of the venular legs of human cutaneous capillaries

F. Jung^{1*}, R.P. Franke¹

¹ GKSS Research Centre Geesthacht, Berlin-Brandenburg Center for Regenerative Therapies (BCRT), Campus Virchow-Klinikum der Charité, Universitätsmedizin Berlin, Germany

Corresponding author:

Prof. Dr. F. Jung
GKSS-Forschungszentrum Geesthacht
Center for Biomaterial Development
Kantstraße 55
14513 Teltow Germany
e-mail: friedrich.jung@gkss.de

Abstract

While structure and function of precapillary sphincter cells were assured in skin capillaries it is unclear whether segmental reduction of capillary lumina can occur in human capillaries. It has been shown that endothelial cells are able to exert dynamical reactions. Since the first description of the vascular endothelium a great variety of findings were described concerning the active role of capillary endothelial cells in regulation of the capillary lumen applying intravital microscopy.

The intravital microscopy was performed in the framework of an observational study to document the long-term stability of capillaries in healthy subjects over many years. In the second year one of the participants showed remarkable changes in capillaries compared to recent recordings. Control recordings were performed 1, 3, 4, 5 and 20 hours after the initial examination – until a complete normalization of the capillaries occurred

This case report is documenting for the first time clearly that extreme luminal narrowing of long segments of cutaneous capillaries can also appear in humans, in this case restricted exclusively to the venular leg of the capillaries. Different from the reductions of the capillary lumen induced by electrical irritation in frogs which lasted only for seconds, the capillary lumen narrowing in this case lasted considerably longer, almost over a whole day.

It is important to note that the demonstrated findings did not occur in all capillaries and it remains unclear whether such findings are restricted to skin capillaries or might occur also in other regions of the body or even systemically. It could be demonstrated clearly, however, that segmental narrowing of capillary lumina can occur in humans possibly leading to a temporary stillstand of perfusion.

Key words:

Microcirculation, erythrocyte column diameter, capillary narrowing

Introduction

While structure and function of precapillary sphincter cells [Herman and D'Amore, 1985; Wiedeman et al., 1976] were assured in skin capillaries [Braverman, 1997] it is unclear whether segmental reduction of capillary lumina can occur in human capillaries [Messmer and Hammersen, 1983]. It has been shown that endothelial cells are able to exert dynamical reactions [Kadi et al., 2007; Stoltz et al., 2007]. Since the first description of the vascular endothelium a great variety of findings were described concerning the active role of capillary endothelial cells in regulation of the capillary lumen applying intravital microscopy [Illig, 1957; Majno et al., 1969; McCuskey, 1966; McCuskey and Chapman, 1969; Rhodin, 1967; Sanders, 1940; Stricker, 1876; Zweifach, 1934]. A buckling of the endothelial cells into the vascular lumen is thought to be responsible for this [Drenckhahn, 1983]. Luebbers et al. especially documented that the electrical stimulation of frog mesentery capillary endothelial cells led to a reduction of the capillary lumen [Lübbers et al., 1979; Weigelt et al., 1979]. Since then it was shown in-vitro that human venous endothelial cells seeded on an extracellular matrix were able to reversibly double their height after chemical stress [Franke et al., 2008]. Anticipating a capillary with a diameter of 8 μm an increase in height of the endothelial cells from 3 to 6 μm would lead to a functional capillary stenosis of nearly 70%, leading to a markedly reduced capillary perfusion [Popel and Pittman, 1995], while such an endothelial buckling is most probably irrelevant for the blood flow in larger vessels.

Here we demonstrate for the first time a case report that segmental reductions of capillary lumina indeed occur in humans. As part of a long-term study performed over 5 years in a group of healthy subjects using intravital capillary microscopy a segmental reduction of capillary lumina was documented in the nailfold of one participant. Serial images of the identical capillaries were taken 1, 3, 4, 5 and 20 hours after the baseline measurement – until the complete normalization of the capillary lumen.

Methods

The intravital microscopy was performed in the framework of an observational study to document the long-term stability of capillaries in healthy subjects over many years. In the second year one of the participants showed remarkable changes in capillaries compared to recent recordings.

The participant was male, 42 years old, non-smoker with normal body weight (body height 173 cm with a body weight of 69 kg). The blood pressure was 125/80 mmHg and the heart rate 74 beats/min. There were no somatic cardiovascular risk factors like diabetes mellitus, hypertension and hyperlipidemia. ECG was normal and ultra sound doppler examinations of the big arteries (A. carotis and A. femoralis at both sides) showed no signs of atherosclerotic lesions. He met the criteria of a “healthy subject” according to the Nordkem-Workshop criteria [Alström et al., 1975].

Intravital video capillary microscopy

The capillaries of the nailfold of the left ring finger were recorded using a video capillary microscope [Fagrell, 1973; Jung et al., 1992]. To visualize single nutritive skin capillaries,

each of them supplying one skin papilla, an angle of 45 degrees between the incident green light (wavelength of 469 nm) and the skin surface was used. Green light is absorbed by the red cell hemoglobin rendering them visible against the non-visible tissue [Fagrell et al., 1977]. Thus it is possible to quantify the size of single erythrocytes or of an erythrocyte column in the capillary lumen [Fagrell et al., 1977; Jung et al., 1992]. The red cell column diameter, however, is not the inner diameter of the capillary. Usually, there is an additional plasma layer around the red cell column which was shown to be 38% bigger than the red cell column diameter [Mahler et al., 1983]. This was validated using different fluorescent microscopy methods labelling different plasma components, thus assessing the capillary volume filled with plasma [Brülisauer and Bollinger, 1993; Mahler et al., 1983]. Arterioles feed red blood cells into the arteriolar leg of the capillary, which then reach the capillary plexus and proceed into the venular leg of the capillary [Brülisauer and Bollinger, 1993]. Three to 4 venular legs of capillaries are drained in general into a gathering venule. Only in the nail fold both capillary legs can be assessed because only here the capillaries are placed in parallel to the skin surface allowing a correct measurement of erythrocyte and capillary diameters. In addition this allows also the direct measurement of erythrocyte velocities in capillaries [Jung et al., 1987; Jung et al., 1992].

Analyses of diameters of single erythrocytes or of red cell columns were performed interactively in 50 lines and reported as mean values \pm standard deviation [Jung et al., 1994]. The vertical resolution of the system was shown to amount to 0.78 μm [Jung et al., 1987].

Red cell velocities in the capillaries were evaluated using three different methods. The frame-to-frame analysis was used as the gold standard [Bollinger et al., 1974], the line-shift method and a cross-correlation-method were applied additionally [Klyszcz et al., 1997]. There were no differences between the 3 methods used. In the manuscript only the results of the frame-to-frame analysis are shown.

The videocapillaroscopy system consisted of an epi-illuminated microscope (Microscope Leica Z16 APO) equipped with an Neofluar objective (6.3/0.20) with a post magnifying lens (optovar 1.0 – 2.0), a cold light source (Schott KL 1500 LCD), a green filter (within the wavelength range of hemoglobin at approx. 560 nm to achieve a good contrast between the red blood cells and tissue), and an infrared filter (to minimize heating of the investigation area), as well as a video camera (Kappa CF8/5 MX DRE) [Jung et al., 1987]. All capillaries were recorded with a final magnification of 1:570. The video sequences were recorded using the image capture system, Framegrabber (Imagenation PXC-200) and a PC (with an Intel Core 2 Duo processor, 1024 MB RAM, 160 GB hard disk, Windows XP Pro), and stored via a DVD recorder (Panasonic LQ-MD800) [Park et al., 2008].

The capillary microscope, methodology, reference ranges and an error analysis have been published previously [Jung et al., 1990].

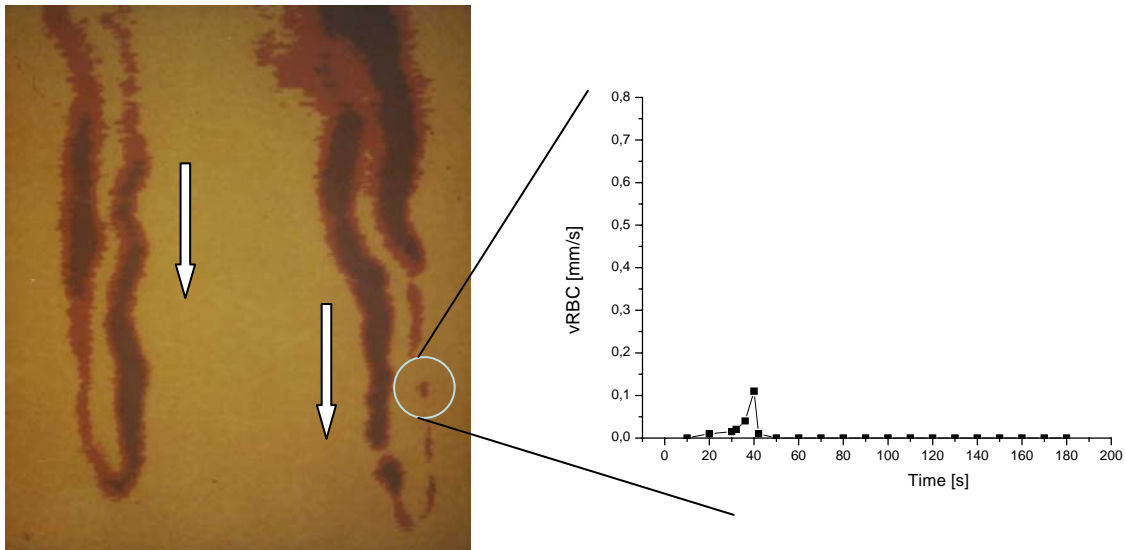
Results

Almost every other capillary at the nailfold of the fourth finger showed narrowing of the erythrocyte column under resting conditions after adaptation to room temperature (skin temperature 27.3 °C). In some of the capillaries these narrowings were so great that the

perfusion was no longer seen. These narrowings occurred in the venular leg of capillaries exclusively starting from the capillary apex, while the erythrocyte column diameter in the arteriolar leg of the capillary was normal. Figure 1 exhibits the central part of the capillary loops in the nailfold of the 4th digit of the left hand.

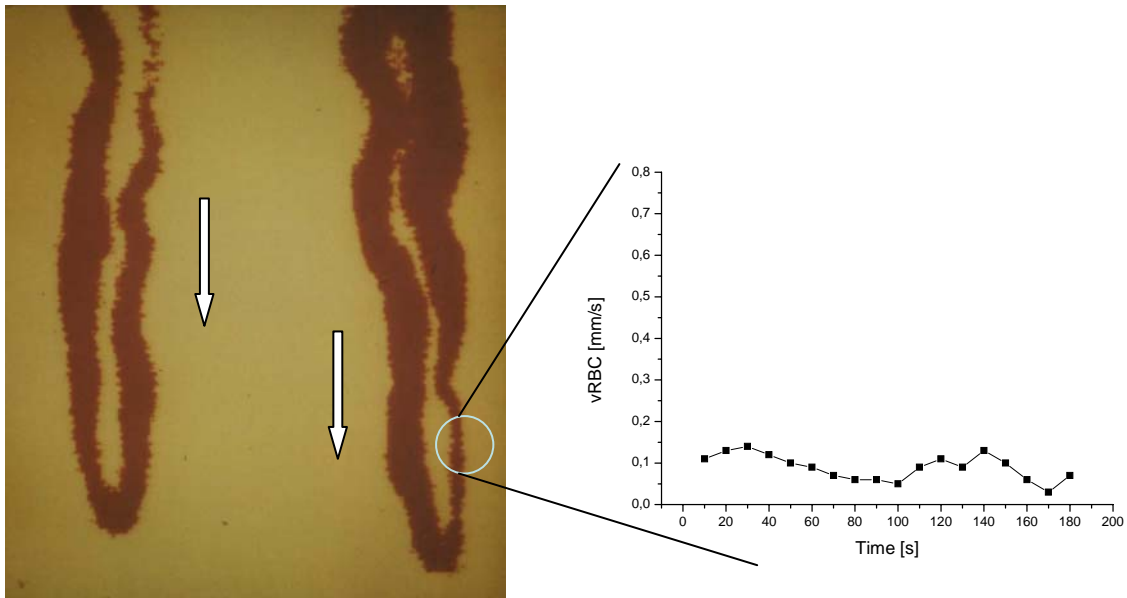
The capillary shown on the right side of this figure was strongly narrowed in the venular leg over a distance of 150 μm . Those erythrocytes passing through this capillary evidently had only a very narrow capillary lumen available leading to a discontinuous perfusion. The capillary shown on the left side of this figure was continuously perfused, although there was a slight narrowing in the venular leg starting right after the capillary apex over a distance of 70 μm .

Figure 1: Segmental reduction of the lumen in the venular leg of neighboured human cutaneous capillaries (Direction of the capillary blood flow is indicated by arrows, final magnification 1:570)



After 4 hours the identical capillaries were recorded again. In both capillaries the length of the capillary segments exhibiting narrowing was reduced down to 70 μm in the right capillary and 15 μm in the left. Also the narrowing of the right capillary was reduced considerably so that now a continuous perfusion was reestablished again.

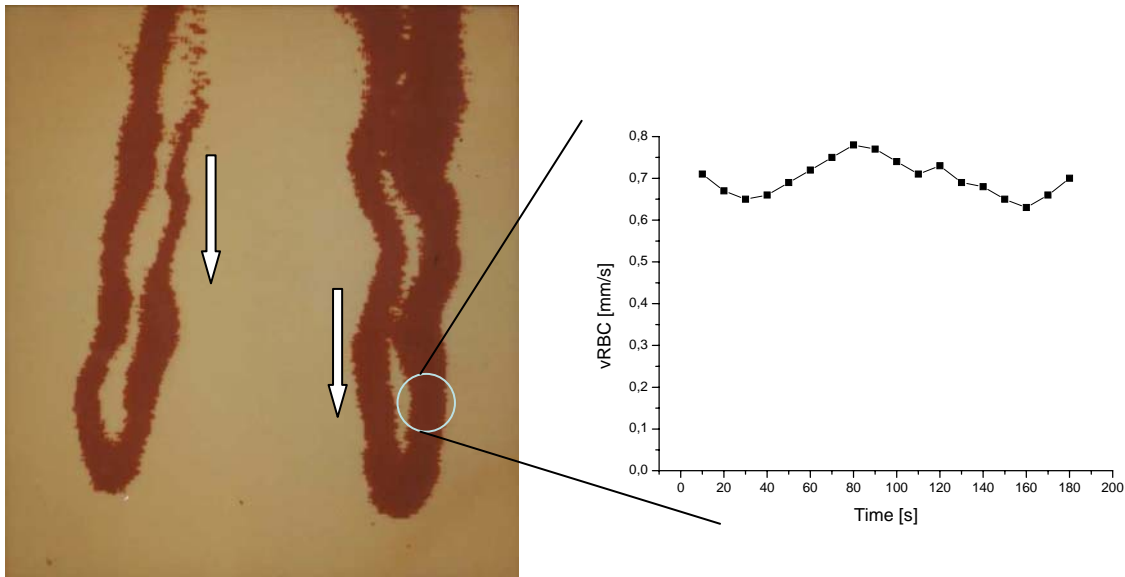
Figure 2: Identical capillaries as in Figure 1, 4 hours later (final magnification 1:570)



Five hours later there was a further reduction in the narrowed capillary passages. The erythrocyte column in the left capillary was back to normal whereas the luminal narrowing of the right capillary had not completely returned to normal. There was continuous perfusion again in both capillaries.

Twenty hours past the first documented finding there was a normal erythrocyte column also in the venular leg of the right capillary and the perfusion had returned to normal ($14.3 \pm 1.25 \mu\text{m}$).

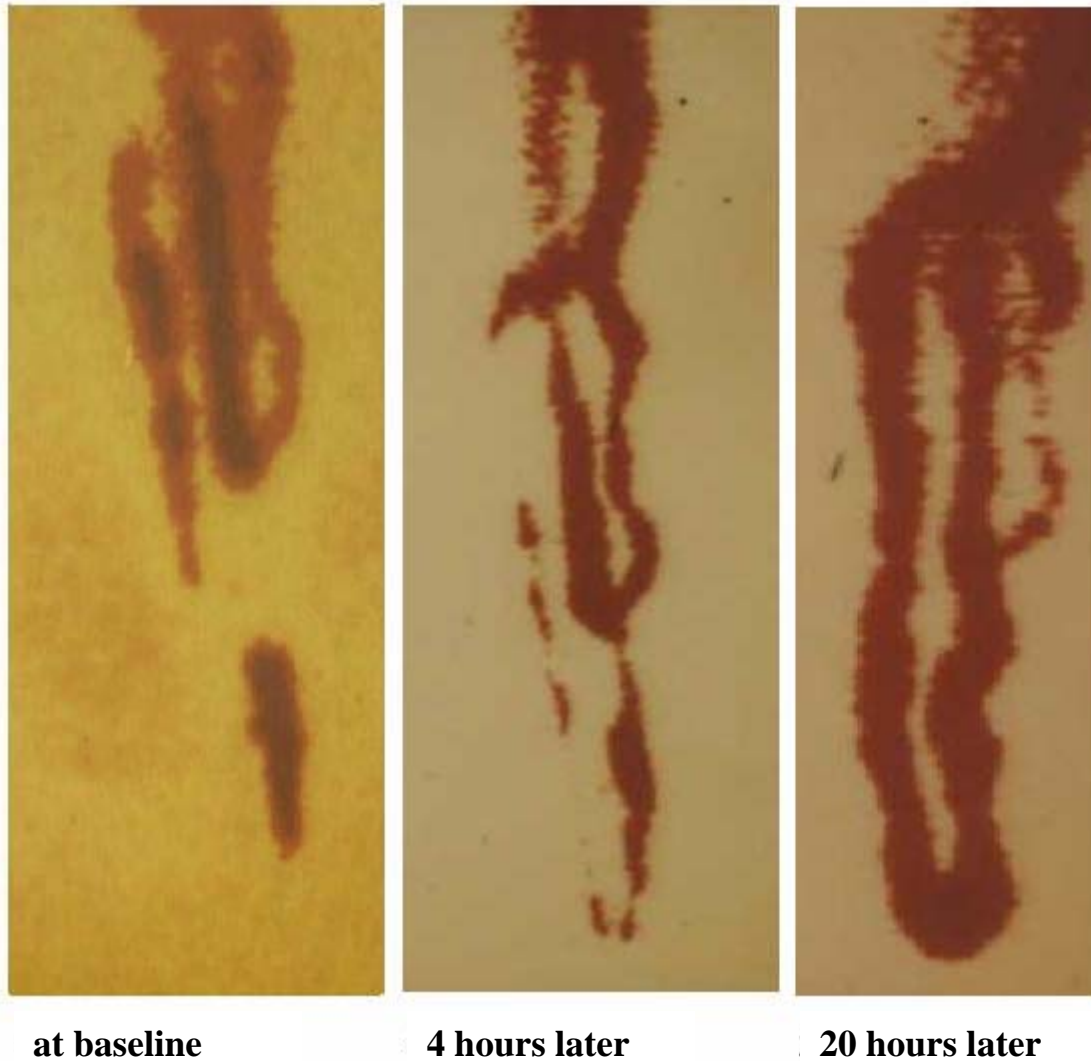
Figure 3: Normal erythrocyte column diameter in the reported capillaries 20 hours later (final magnification 1:570)



In these and also in the neighbored capillaries there were almost no longer alterations visible. All of the capillaries were normally perfused now; irreversible occlusions (capillary thromboses or microvascular obstructions) could not be detected.

Another example is demonstrated in Fig. 4 showing a further capillary at the different time points documented in the previous figures. In the left part of fig. 4 there is a complete stillstand of the capillary perfusion at baseline. In some segments of the capillary stationary aggregated erythrocytes were seen. The trajectory of the capillary is not completely visible because only hemoglobin (of the erythrocytes) renders them visible using green light illumination, but neither the capillary wall nor the blood plasma. In the central part of figure 4 this capillary is shown 4 hours later. It is evident that erythrocytes had to become very narrow in order to be able to pass the venular leg of the capillary due to the extremely narrow lumen of this capillary. Three erythrocytes can be observed passing the narrow capillary lumen at a very low speed. Twenty hours past the original finding the lumen of the venular leg of the capillary had returned to normal ($13.5 \pm 1.21 \mu\text{m}$) and so had a perfusion (right part of fig.4)

Figure 4: Nailfold capillary documented at 3 points of time (final magnification 1:570)



In the year following these events there were some further examinations. In almost all cases normally perfused capillaries were found. There was 1 exemption when there was again a clear reduction in the venular leg of a capillary which, however, did not show a temporary stillstand of perfusion.

Discussion

In animal experiments it was shown that inflammatory irritation (application of e.g. histamine, serotonin, adrenalin or bradykinin) induced inter-endothelial gaps in postcapillary venules [Arrick et al., 2007; Conde et al., 2007; Joris et al., 1972; Majno et al., 1969; Oishi et al., 2007; Wolf and Weigelt, 1985]. It is thought that endothelial cells

are instrumental in the development of inter-endothelial gaps and in the buckling of endothelial cells into the capillary lumen [Joris et al., 1972; Braverman, 1997]. There is still a controversy about the active contractile elements in endothelial cells responsible for development of endothelial cell contraction, of cell buckling and of inter-endothelial gaps [Herman and D'Amore, 1985; Nehls and Drenckhahn, 1991]. It is unclear how the actin-myosin filaments are composed of e.g. muscular or non-muscular myosins in different parts of the vasculature especially of the capillary bed. This case report gives evidence that there could be different components in the actin-myosin system in endothelial cells either of the venular or of the arteriolar leg of capillaries.

While contractile pericytes were thought to be the acting elements in earlier work [Krogh, 1929] it was shown later in capillaries of frogs that capillary endothelial cells were able to buckle into the capillary lumen and to slow down perfusion up to a complete stasis [Clark and Clark, 1935; Lübbers et al., 1979; Sanders et al., 1940; Sandison, 1932; Weigelt, 1982; Zweifach, 1934]. Further examinations on the capillary system of the frog mesentery demonstrated that there are specialized and electrically excitable capillary endothelial cells localized distally of precapillary sphincters [Chambers and Zweifach, 1940; Illig, 1957, Rhodin, 1967]. Lübbers and his group described the function of these specialized endothelial cells as additional regulators for the fine tuning of the blood flow in the microcirculation [Weigelt, 1982]. The density of these effector cells was described to be about 2% of all capillary endothelial cells and appears to be very low [Drenckhahn, 1983, Weigelt, 1982]. They were characterized to have high contents of microfilaments, intermediate filaments and Weibel Palade bodies.

Specialized capillary endothelial cells which could be compared to these effector cells have not been described in mammals so far. There were a few descriptions of endothelial protrusions in capillaries of mammals occurring either spontaneously [McCuskey, 1966; McCuskey and Chapman, 1969] or due to electrical irritation [Weigelt et al, 1979a; Weigelt et al., 1979b]. These findings are still discussed controversially [Messmer and Hammersen, 1983].

Such findings were not described so far in humans. This case report is documenting clearly that extreme segmental luminal narrowing of cutaneous capillaries also appear in humans, in the case described restricted exclusively to the venular leg of the capillaries (see figure 1). Different from the reductions of the capillary lumen induced by electrical irritation in frogs which lasted only for seconds, the capillary lumen narrowing in this case lasted considerably longer almost over a whole day.

It is important to note that the demonstrated findings did not occur in all capillaries and it remains unclear whether such findings are restricted to skin capillaries or might occur also in other regions of the body or even systemically. It could be demonstrated clearly, however, that segmental narrowing of capillary lumina can occur in humans possibly leading to a temporary stillstand of perfusion.

References

- Alström, T., et al., 1975. Recommendations Concerning the Collection of Reference Values in Clinical Chemistry and Activity Report. *Scand. J. Clin. Lab. Invest.* 35, 1-74.
- Arrick, D. M., et al., 2007. Diabetes-induced cerebrovascular dysfunction: role of poly(ADP-ribose) polymerase. *Microvasc. Res.* 73, 1-6.
- Bollinger, A., et al., 1974. Red blood cell velocity in nailfold capillaries of man measured by a television microscopy technique. *Microvasc. Res.* 7, 61-72.
- Braverman, I. M., 1997. The cutaneous microcirculation: ultrastructure and microanatomical organization. *Microcirculation.* 4, 329-340.
- Brülisauer, M., Bollinger, A., 1991. Measurement of different human microvascular dimensions by combination of videomicroscopy with Na-fluorescein (NaF) and indocyanine green (ICG) in normals and patients with systemic sclerosis. *Int. J. Microcirc. Clin. Exp.* 10, 21-31.
- Chambers, R., Zweifach. B.W., 1944. Topography and function of the mesenteric capillary circulation. *Am. J. Anat.* 75, 173-205.
- Clark, E.R., Clark, E.L., 1935. Observations on changes in blood vascular endothelium in the living animal. *Am. J. Anat.* 57, 385-438.
- Conde, C. M., et al., 2007. Longchain n-3 polyunsaturated fatty acids and microvascular reactivity: observation in the hamster cheek pouch. *Microvasc. Res.* 73, 237-47.
- Drenckhahn, D., 1983. Zellmotilität und zytoplasmatische Filamentsysteme in Gefäßendothelzellen. In: K. Messmer, F. Hammersen (Eds). *Struktur und Funktion endothelialer Zellen.* Karger Verlag, Basel, 60-79.
- Fagrell, B., 1973. Vital Capillary Microscopy – Method for Evaluating Effect of Therapeutic Procedures on Ischemic Skin Ulcers. *Acta Physiol. Scand.*, 99.
- Fagrell, B., et al. 1977. A microscope television system for studying flow velocity in human skin capillaries. *Am. J. Physiol.* 233, H318 – H321.
- Franke, R.P., et al., 2008. Influence of various radiographic contrast media on the buckling of endothelial cells. *Microvasc. Res.* 76, 110-113.
- Herman, I. M., D'Amore, P. A., 1985. Microvascular pericytes contain muscle and nonmuscle actins. *J. Cell Biol.* 101, 43-52.
- Illig, L., 1957. Capillar"Contractilität", Capillar"Sphinkter" und Zentralkanäle ("A.-V.-Bridges"). Ein tierexperimenteller Beitrag zur motorischen Funktion und zum Aufbau des Capillarbettes mit Schrifttumsübersicht. *Wien. Klin. Wochenschr.* 35, 7-22.
- Joris, I., et al., 1972. Endothelial contraction in vivo: a study of the rat mesentery. *Virchows Arch. B Cell Pathol.* 12, 73-83.
- Jung, F., et al., 1987. Video Capillary Microscopy – Determination of Geometrical and Dynamic Parameters. *Biomed. Tech. (Berl).* 9, 204-213.
- Jung, F., et al. 1990. Error analysis, biological influencing factors, and variance of periungual video capillary microscopy. *Biomed. Tech. (Berl).* 35, 195-204.
- Jung, F., et al. 1992. Interactive image processing system for cutaneous video capillary microscopy: methodology and clinical application. *Biomed. Optronics.* 1, 27-35.

- Jung, F., et al., 1994. [Computer assisted analysis of the morphology of cutaneous capillaries in human intravital microscopy]. *Bildgebung*. 61(4), 277-83.
- Kadi, A., et al., 2007. Potential relation between cytoskeleton reorganization and e-NOS activity in sheared endothelial cells (Effect of rate and time of exposure). *Clin. Hemorheol. Microcirc.* 37,131-140.
- Klyszcz, T., et al., 1997. [Cap image--a new kind of computer-assisted video image analysis system for dynamic capillary microscopy]. *Biomed Tech (Berl)* 42, 168-75.
- Krogh, A., 1929. *The anatomy and physiology of capillaries*. Yale University Press, New Haven.
- Lübbers, D. W., et al. 1979. Contractile properties of frog capillaries tested by electrical stimulation. *Bibl. anat.* 17, 3-10.
- Mahler, F., et al., 1983. In vivo comparison of the nailfold capillary diameter as determined by using the erythrocyte column and FITC-labelled albumin. *Int. J. Microcirc. Clin. Exp.* 2, 147-55.
- Majno, G., et al., 1969. Endothelial contraction induced by histamin-type mediators. *J. Cell Biol.* 42, 647-671.
- McCuskey, R., 1966. A dynamic and static study of hepatic arterioles and hepatic sphincters. *Am. J. Anat.* 119, 455-478.
- McCuskey R.S., Chapman T. M., 1969. Microscopy of the living pancreas in situ. *Am. J. Anat.* 126, 395-408.
- Messmer, K., Hammersen, F., 1983. *Struktur und Funktion endothelialer Zellen*. Karger Verlag, Basel, 112 – 114.
- Nehls, V., Drenckhahn, D., 1991. Heterogeneity of microvascular pericytes for smooth muscle type alpha-actin. *J. Cell. Biol.* 113, 147-154.
- Oishi, K., et al., 2007. Isometric contraction of microvascular pericytes from mouse brain parenchyma. *Microvasc. Res.* 73, 20-8.
- Park, J.W., et al., 2008. Cutaneous microcirculatory function predicts the responsiveness to tadalafil in patients with erectile dysfunction and coronary artery disease. *Int. J. Impot. Res.* 20,150-156.
- Popel, A. S, Pittman, R.N., 1995. Mechanics and transport in the microcirculation. In: JD Bronzino, (Ed.), *The Biomedical Engineering Book..* CRC Press, Boca Raton, 1995; 463.
- Rhodin, J. A., 1967. The ultrastructure of mamalian arterioles and precapillary sphincters. *J. Ultrastruct. Res.* 18, 181-223.
- Sanders, R., et al., 1940. The mechanism of capillary contraction. *Q. J. Exp. Physiol.* 30, 281-285.
- Sandison, J. C., 1932. Contraction of blood vessels and observations on the circulation in the transparent chamber in the rabbits ear. *Am. J. Anat.* 54, 105-112.
- Stoltz, J.F., et al., 2007. Introduction to endothelial cell biology. *Clin. Hemorheol. Microcirc.* 37(1-2), 5-8.
- Stricker, G., 1876. Untersuchungen über die Contractilität der Kapillaren. *Sitzungsberichte der Wiener Akademie der Wissenschaften, math.-naturwiss. Klasse*, 74, Abt. 3, 313 – 332.
- Weigelt, H., 1982. Die spezialisierte Endothelzelle - erregbare Zelle und mechanischer Effektor der Mikrozirkulation. *Funkt. biol. Med.* 1: 53-60.

- Weigelt, H., et al., 1979a. Vitalmicroscopic studies in regard to the role of intraendothelial reactive structures in the inflammatory process. *Bibl. anat.* 17, 11-20.
- Weigelt, H., et al., 1979b. A vitalmicroscopic set-up to study vasomotion induced by electrical stimulation with microelectrodes. *Bibl. anat.* 18, 81-84.
- Wiedeman, M. P., et al., 1976. Defining the precapillary sphincter. *Microvasc. Res.* 12, 71 – 75.
- Wolf, E. K., Weigelt, H. H. 1985. In vivo microapplication of adrenaline to capillaries in frog mesentery. *Microcirc. Endothelium. Lymphatics.* 2, 607-615.
- Zweifach, B. W., 1934. A micro-manipulative study of blood capillaries. *Anat. Rec.* 59, 83-108.